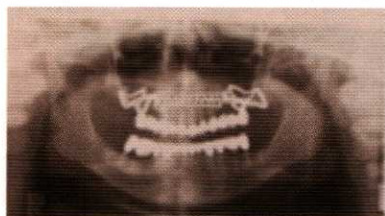


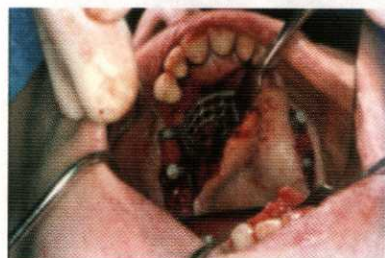


## A Periodontal Perspective of Mini Dental Implants— The Friendly Dental Implants

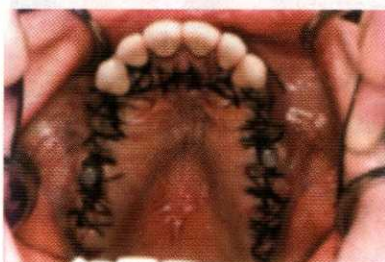Harry A. Haralampopoulos, DDS, MS, FAGD, Nikol H. Haralampopoulos, DMD



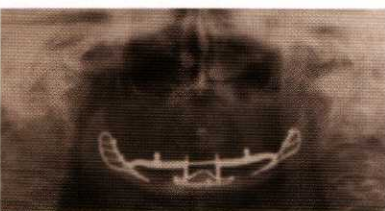
(Fig 1)



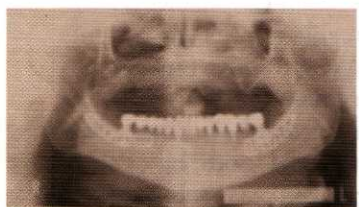(Fig 2)



(Fig 3)



(Fig 4)



(Fig 5)

### Introduction

As a profession, dentistry has the honorable objective of preserving and caring for natural teeth through periodontic, endodontic, orthodontic, and restorative treatment. Even a single missing tooth can adversely affect the life of an individual. Losing a molar disrupts chewing, while losing an incisor can alter appearance, speech, self-esteem, and relationships. In spite of our best efforts, “more than 35 million Americans do not have any teeth, and 178 million people in the U.S. are missing at least one tooth—and those numbers are expected to grow in the next two decades.”<sup>1</sup> For these individuals, dentistry has traditionally provided fixed and removable prostheses to replace the missing teeth. In the last 30 years, traditional and small diameter, (mini), endosseous dental implants have emerged to assist, replace, and improve these traditional therapies. Although traditional, wider implants provide effective solutions for replacing missing teeth, this article will concentrate on the periodontal advantages of mini dental implants—the friendly dental implants.

### Dental Implants—from Larger to Smaller

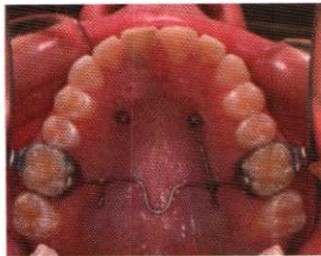
The modern iteration of the dental implant occurred in the twentieth century with the engineering of various systems. Through the years, dental implants have generally progressed from larger to smaller sizes and from more complicated to less complicated surgical procedures. An example showing the complexity of first generation dental implantology is exhibited by the following surgical case. In 1986, the female patient depicted, (figure 1), had her posterior teeth restored with two mandibular, stock blade implants and one large, bilateral maxillary subperiosteal implant. The maxillary procedure involved incision and reflection of palatal tissue to gain an impression of palatal and alveolar bone. A few weeks later, a similar surgical incision was performed to reopen the palatal tissue for delivery of the maxillary subperiosteal implant (figures 2 and 3). Also presented, (figure 4), is a mandibular subperiosteal implant which required delicate and extensive surgery to avoid the exiting neurovascular bundle from the mental foramen (figure 4). A third case, completed in 1984, involved the placement of large, custom designed and fabricated blade implants. These implants were free-handedly placed bordering the superior aspect of the mandibular canal (figure 5). All of these cases involved much more invasive, traumatic, and complicated surgical procedures than would be necessary by using smaller, mini dental implants.

Although mini dental implants were developed over 25 years ago<sup>2</sup>, it is just recently that they have been accepted as being successful restoratively and periodontally. As the ancient Greek poet Theognis stated, “Don’t rush. There is a perfect moment for everything we do.”<sup>3(p114)</sup> Now is that, “perfect moment”, for mini dental implants.

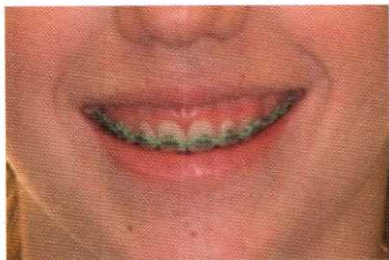



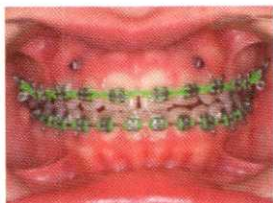(Fig 6)



(Fig 7)



(Fig 8)



(Fig 9)



(Fig 10)

## Statistics and More

Although mini dental implants have less quantitative surface area than wider implants, studies have shown that the diameter of implants is not a significant factor in their survival.<sup>4,5,6</sup> Contrary to implant width, length is significant. Research has shown implants shorter than 10 mm had a lower survival rate than implants longer than 10mm.<sup>6</sup>

Studies involving mini dental implants report similar success rates as traditional, wider implants. A study evaluating 1387 traditional dental implants supporting single tooth crowns reported a success rate of 93.1%.<sup>7</sup> A similar 10-year study following 285 traditional implants supporting overdentures indicated a success rate of 95.4%.<sup>8</sup> In comparison, a 2-year, 11 patient retrospective study of 2.4 mm diameter implants supporting a single tooth crown reported only 1 unsuccessful implant, resulting in a mini implant survival rate of 90.9%.<sup>9</sup> Another study involved 24 patients ranging in age from 50 to 90 years old. Of the 116 mini dental implants placed to stabilize dentures, 113 survived, for a rate of 97.4%.<sup>2</sup> A 5-year retrospective study was conducted involving 531 patients with 2514 mini dental implants. The mini implants were used to support maxillary and mandibular fixed and removable prostheses and demonstrated a success rate of 94.2%.<sup>10</sup>

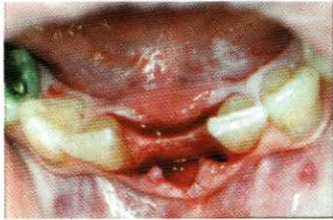Research shows that mini dental implants can be immediately loaded when their placement torque is greater than 35Ncm.<sup>11</sup> In contrast, loading is usually postponed with traditional endosseous dental implants.<sup>12</sup>

Since the Food and Drug Administration has approved the long-term use of various mini dental implant systems,<sup>3,10</sup> dental practitioners can feel confident in their use. In the words of Aristotle, "Anything that we have to learn to do, we learn by the actual doing of it."<sup>2(p.137)</sup>

## Small but Mighty

The strength and versatility of mini implants can be observed by considering their recent accomplishments in orthodontics. Orthodontic mini dental implants, called temporary anchorage devices,<sup>13(p.238)</sup> have the ability to "move the whole detention of each arch,"<sup>13(p.223)</sup> with skeletal anchorage replacing traditional extra-oral headgear devices.<sup>14</sup> Contrast the maxillary arch advancement experience of the patient wearing an extra-oral headgear device, (figure 6), with the patient using a transpalatal bar and two temporary anchorage devices, (figure 7). Another case depicts two buccally positioned temporary anchorage devices to intrude the maxillary arch and improve the gummy appearance of the patient's smile, (figures 8, 9, 10). These specialized mini implant procedures are obviously friendlier to the patient than burdensome headgear or invasive orthognathic surgery. smaller, mini dental implants.

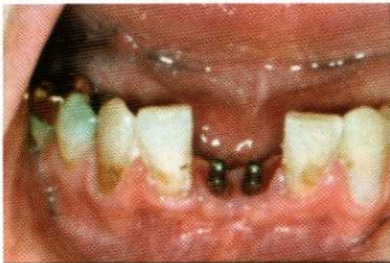



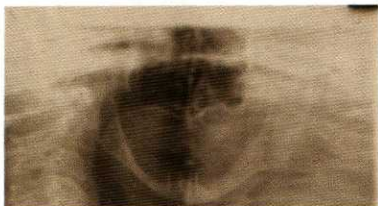(Fig 11)



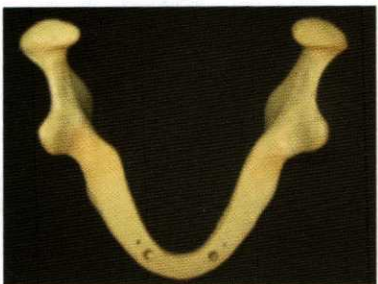
(Fig 12)



(Fig 13)



(Fig 14)



(Fig 15)

## Space Considerations

The main differentiating feature between traditional implants and mini implants is their width and not their length. Generally, traditional dental implants need an alveolar ridge wider than 5 mm, while mini dental implants can be placed in ridges 3 to 4 mm wide.<sup>11, 15</sup>

When considering the placement of implants in atrophic ridges with insufficient bone quantity, mini dental implants are friendlier to the patient and to the periodontium than traditional implants. Accommodating traditional, wider implants in these deficient ridges would necessitate either bone grafting to add bone, or resection of the coronal aspect of the ridge to remove bone until an adequate width of bone is obtained. Sometimes, 6 to 7 mm of osseous height must be removed.<sup>16</sup> Bone grafting procedures complicate and prolong the surgical process for the patient, while an osteotomy harms the periodontium by accelerating the loss of natural, edentulous bone that ordinarily takes years to resorb. Reducing a patient's natural bone, in a situation where there already is a lack of bone, contradicts basic periodontal principles of preserving bone. The patient portrayed, (figure 11), has a narrow buccal-lingual alveolar ridge and an undersized mesial-distal span between the roots and the coronal portions of teeth #23 and #26 (Figure 12). Even with ridge augmentation, the mesial-distal space is too narrow for traditional implant supported crowns to replace missing teeth #24 and #25. Because of the aforementioned reasons, two mini dental implants were selected. The final restorations exhibit esthetic gingival contours with natural emergence profiles.

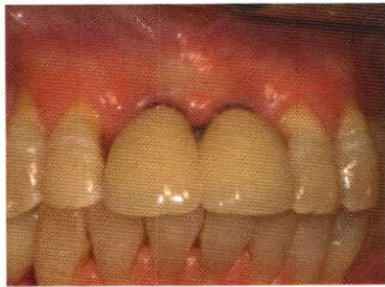Although buccal-lingual narrowness and insufficient mesial-distal spans are common challenges, deficient bone height in the occlusal-apical direction is another consideration. Edentulous areas over the mandibular canal and under the maxillary sinus in atrophied ridges pose special implant placement challenges. In the severely resorbed mandible, (figure 14), placing traditional, wide implants would require removing a considerable volume of bone, possibly weakening the mandible and increasing its chance for fracture. The placement of mini dental implants in this mandible eliminated the previously mentioned risk factors.

The three main sources of blood supply to the periodontium are the periodontal ligament vessels, arterioles passing through the alveolus, and suprapariosteal arterioles in the gingiva overlying the buccal and lingual surfaces of the alveolus.<sup>17 (p.28)</sup> With the extraction of a tooth and loss of the periodontal ligament, blood supply to the alveolus and gingiva is reduced.<sup>19</sup>

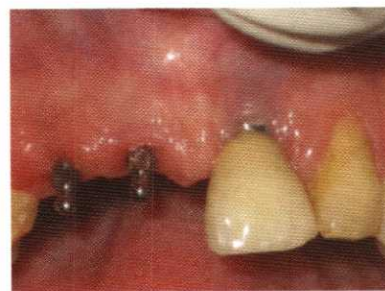The most valuable fluid and tissues in dental implant therapy are the blood, the bone, and the gingiva. Survival of implants depends on the mutual integrity of these components. In order for osteogenesis to occur, the new bone formation requires living osteoblasts nourished by an adequate blood supply.<sup>17 (p.907)</sup> Tooth extraction and implant placement reduces blood supply, predisposing an implant for recession and exposure, especially when the remaining buccal bone is thin, cortical, and less vascular.<sup>18</sup> Because of this, techniques and procedures protecting the blood supply are preferable when placing dental implants. Avoiding ridge resection to maintain its entirety, using a smaller osteotomy, maintaining an adequate zone of attached gingiva, and using flapless procedures to preserve blood supply to the bone and gingiva greatly enhance implant success.

The osteotomy size for a mini dental implant is significantly smaller than a traditional implant, (figure 15). As osteotomies are prepared larger and





(Fig 16)



(Fig 17)

occupy more of the alveolus, the blood supply lessens, and healing is delayed.<sup>18</sup> Consequently, the diminished blood flow to the osseous crest may account for the typical resorption around the first thread observed in larger implants and not usually apparent in 2 mm diameter implants.<sup>9</sup> The immediate loading success of mini dental implants can possibly be attributed to smaller osteotomies and accompanying flapless procedures which tend to respect the alveolar and gingival blood supplies.

### Implant Recession

Recession, whether observed on natural teeth or dental implants, is most likely caused by analogous etiology. Both teeth and implants must have a biological protective seal, or biologic width, to shield the periodontal and peri-implant bone from disease and infection.<sup>18,19</sup> The biologic width of approximately 2 mm must be maintained from the crest of alveolar bone, while a restoration margin must be at least 3 mm from this alveolar crest.<sup>17 (pp.945,950), 19</sup>

Although there are various reasons for recession, such as aggressive tooth brushing, thin attached gingiva, or occlusion, the position of a tooth within the alveolus may be the key determining factor.<sup>17 (p.276)</sup> When a tooth is malpositioned outside of the alveolar housing or has a prominent protrusive root, a dehiscence or absence of the cortical plate develops.<sup>17 (pp.50,51)</sup> To successfully correct this associated recession on a natural tooth with connective tissue or gingival grafting, the root must be brought within the bony housing of the alveolus by root planning, orthodontics, or odontoplasty.<sup>17 (p.862),20,21</sup> Similarly, as in natural teeth, an implant positioned exceedingly close to the thin, cortical housing can diminish the overlying bone and result in recession.<sup>18</sup> The recession demonstrated around two maxillary central incisors, (figure 16), exposing the underlying traditional implants, may be related to a combination of thin buccal bone, thin attached gingiva, and the protrusive forces of occlusion. Considering the recession on the patient's adjacent teeth, (figure 17), perhaps a mini dental implant would have allowed a more centered position within the alveolar ridge, thus preserving more buccal bone.

Studies have shown a basic requirement to prevent labial recession and maintain esthetics around a dental implant is to position the implant within the alveolus, maintaining at least a 2 mm thickness of buccal bone overlying the implant.<sup>22</sup> In addition, there is a soft tissue requirement of 3mm attached gingiva over this bone.<sup>22</sup>

The soft tissue thickness requirement of 3 mm buccal attached gingiva is often accomplished through soft tissue grafting proceeding or following implant placement, or through raising mini flaps to preserve the gingiva. Other techniques involve flapless procedures associated with the use of mini dental implants.

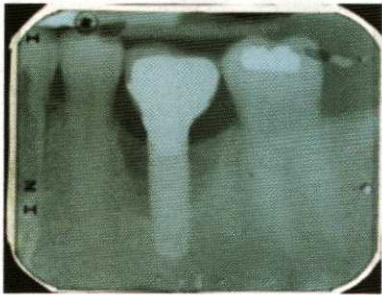
Some two-piece traditional implants use platform switching to help fulfill the soft and hard tissue requirements. Platform switching reduces the approximate one millimeter of crestal bone loss that typically occurs with two-piece implants by placing a smaller abutment head on a larger implant body and shifting the microgap inward, closer to the center of the implant body.<sup>23,24,25</sup> This modification thickens the biological protective seal, increases attached gingiva, and moves inflammatory infiltrate away from the bone; thus reducing the negative influence of the microgap.<sup>24,25</sup>



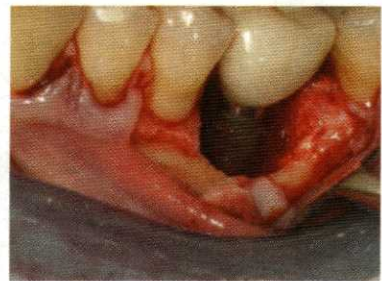


# CASE STUDIES

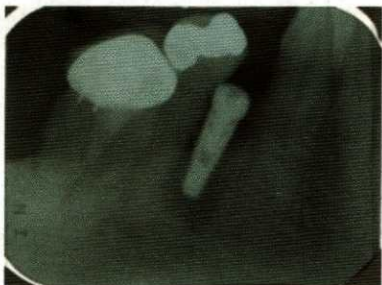*integrity-compassion-education-research-fellowship*



(Fig 18)



(Fig 19)



(Fig 20)



(Fig 21)

By nature of their narrower, one-piece non-microgap design, mini dental implants allow more thickness of the gingiva than usually obtained from platform switching. This narrowness also promotes a thicker biological protective seal. The ability to center mini dental implants on top of an alveolar ridge can be observed in a case of traditional implants next to mini implants (figure 17). In the patient depicted, a comparison of the gingival recession around the traditional implant supported crown, tooth #9, can be contrasted with the abundance of healthier, attached gingiva around the mini dental implant supported crowns of teeth areas #7 and #8. The mini dental implant's smaller diameter allows a centered placement securely enclosed within the housing of the alveolus, better fulfilling the bony and soft tissue thickness requirements.

## Implants Can Fail

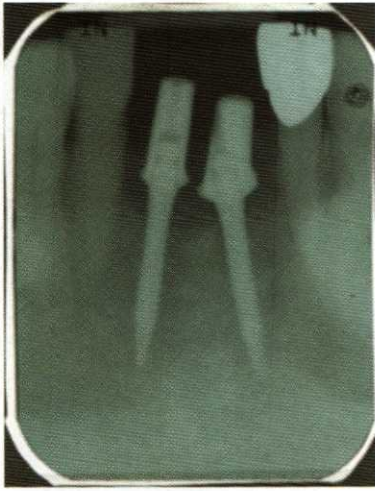While most discussions center on the positive aspect of implant survival, approximately one in ten<sup>9</sup> or one in twenty<sup>8,10</sup> implants fail. Unfortunately, there is no way to predetermine which implants will fail and which will last. When traditional implants fail, the osseous damage is extensive (Figures 18 and 19). If a mini dental implant fails, the implant simply screws out, leaving a small hole that quickly regenerates, similar to an extraction socket. Research has shown bone grafting is not necessary when there is a bone gap less than a few millimeters, even in between an implant surface and an extraction socket.<sup>26</sup>

Depicted, (figure 20), is a damaged periodontium after traditional implant placement and subsequent failure. Regenerative surgical procedures were performed, regaining only enough bone for a mini dental implant. Treating a failing traditional, wider implant can be exhaustive, trying, and expensive, especially if the prosthesis must be replaced. Contrast this scenario with simply "backing out" the loose mini dental implant. One can then either wait for natural healing or just move the implant to an adjacent available space and immediately modify, retrofit, or redo the overdenture or crown.

## Avoiding the Maxillary Sinus

Mini dental implants can often be placed to avoid the maxillary sinus, usually in the area previously occupied by the palatal root. Even if a two-dimensional periapical or panoramic radiograph shows deficiency of bone directly over the sinus, adequate bone to accommodate a mini dental implant may exist medial to the maxillary sinus (Figure 21). In a comparable sinus, placement of a traditional implant would generally have to rely on a sinus elevation and osseous augmentation procedure.





(Fig 22)

## Nonparallel Mini Implants

Paralleling mini dental implants is often more difficult than paralleling traditional wider implants. Since the initial osteotomy is so narrow, mini dental implants can be deflected into different directions by the bone trabeculae during insertion. Even though this might seem to be a disadvantage, studies have shown the tripod effect of implants is more resistant to lateral forces than parallel implants placed in a straight line.<sup>29</sup> "The bending moment on a 3-implant restoration can be reduced by 20% to 60% if the implants can be offset by only 2 to 3 mm from a straight linear relationship."<sup>27</sup> Perhaps this angling of implant bodies into different directions of the supporting bone is an additional reason for the high stability of restorations supported by mini dental implants.

As the ancient Greek poet Hesiod said, "If you add a little to a little, and then do it again, soon that little shall be much."<sup>2(p143)</sup> The process of adding one implant to another, with a little angle here and a little angle there, can provide enough support for fixed and removable prostheses. Whereas overdentures compensate for nonparallel implant placement by the use of o-rings, fixed bridges can accommodate nonparallelism by straight or angled cementable abutments (Figure 22).

## Conclusion

Dental implants are not a new human experience. As early as 600 A.D., dental implants were found osseointegrated in a female Mayan mandible, "which had tooth-shaped shells implanted into the sockets of three lower incisor teeth."<sup>29</sup> In modern times, implants seem to have moved in the direction of larger to smaller, from complicated surgical procedures to flapless techniques; with ever increasing respect to the alveolar bone, gingiva, and blood supply. This is consistent with the periodontal perspective to preserve the bone, the gingiva, and the blood supply, while adequately providing a functional, esthetic prosthesis.

As Xenophon stated, "Nature does not aim to deceive."<sup>2(p.149)</sup> The advent of mini dental implants has afforded both patients and practitioners an advantageous opportunity to replace missing teeth. Immediate loading, use in narrow ridges and spaces, ease of placement and proper positioning, and flexibility of solving restorative and failing implant challenges are some of the practical reasons to utilize mini dental implants—the friendly dental implants.





## Bibliography

1. *Change Your Life*. American College of Prosthodontists Web site.  
<https://www.prosthodontics.org/UserFiles/File/ACP>  
*Change Your Life (Dentures) Brochure Sample.pdf*. Accessed May 8, 2012.
2. Stavropoulos, S. *The Wisdom of the Ancient Greeks: Timeless Advice on the Senses, Society, and the Soul*. New York: Barnes & Noble; 2003.
3. Griffiths TM, Collins CP, Collins PC. Mini dental implants: An adjunct for retention, stability, and comfort for the edentulous patient. *Oral Surg Oral Med Oral Pathol Oral Radiol Endod*. 2005;100(5):e81-e84.
4. Olate S, Lyrio MC, de Moraes M, Mazzonetto R, Moreira RW. Influence of diameter and length of implant on early dental implant failure. *J Oral Maxillofac Surg*. 2010;68(2):414-419.
5. Lee JH, Frias V, Lee KW, Wright RF. Effect of implant size and shape on implant success rates: A literature review. *J Prosthet Dent*. 2005;94(4):377-381.
6. Jang HW, Kang JK, Lee K, Lee YS, Park PK. A retrospective study on related factors affecting the survival rate of dental implants. *J Adv Prosthodont*. 2011;3(4):204-215.
7. Levin L, Sadet P, and Grossmann Y. A retrospective evaluation of 1,387 single-tooth implants: A 6-year follow-up. *J Periodontol*. 2006;77(12):2080-2083.
8. Schwartz-Arad D, Kidron N, and Dolev E. A long-term study of implants supporting overdentures as a model for implant success. *J Periodontol*. 2005;76(9):1431-1435.
9. Balaji A, Mohamed JB, Kathiresan R. A pilot study of mini implants as a treatment option for prosthetic rehabilitation of ridges with sub-optimal bone volume. *J Maxillofac Oral Surg*. 2010;9(4):334-338.
10. Shatkin TE, Shatkin S, Oppenheimer BD, Oppenheimer AJ. Mini dental implants for long-term fixed and removable prosthetics: a retrospective analysis of 2514 implants placed over a five-year period. *Compend Contin Educ Dent*. 2007;28(2):92-99.
11. Lerner H. Minimal invasive implantology with small diameter implants. *Implant Pract*. 2009;2(1):30-35.
12. Birang R, Tavakoli M, Shahabouei M, Torabi A, Dargahi A, Soolari A. Investigation of peri-implant bone healing using autologous plasma rich in growth factors in the canine mandible after 12 weeks: a pilot study. *Open Dent J*. 2011;5:168-173.
13. Nanda R, Uribe FA. *Temporary Anchorage Devices in Orthodontics*. St. Louis, MO: Mosby; 2009.
14. Bratu CD, Pop RV, Pop SI, Bratu EA. Adjusting dento-alveolar morphology with orthodontic mini-implants (miniscrews). A clinical case report. *Rom J Morphol Embryol*. 2011;52(3 Suppl):1133-1137.

15. Preoteasa E, Mele canu-Imre M, Preoteasa CT, Marin M, Lerner H.  
*Aspects of oral morphology as decision factors in mini-implant supported overdenture.*  
*Rom J Morphol Embryol.* 2010;51(2):309-314.
16. Bockhorst BC. *An interview with Dr. Michael McCracken.*  
*Inclusive Magazine.* 2011;2(4):15-19.
17. Newman MG, Takei HH, Carranza FA.  
*Clinical Periodontology.* 9th ed. Philadelphia, PA. W.B. Saunders; 2002.
18. Makigusa K. *Histologic comparison of biologic width around teeth versus implant: The effect on bone preservation.* *J Implant Reconstr Dent.* 2009;1(1):20-24.
19. Gargiulo AW, Wentz FM, Orban B.  
*Dimensions and relations of the dentogingival junction in humans.*  
*J Periodontol.* 1961;32(3):261-267.
20. McLeod DE, Reyes E, Branch-Mays G.  
*Treatment of multiple areas of gingival recession using a simple harvesting technique for autogenous connective tissue graft.* *J Periodontol.* 2009;80(10):1680-1687.
21. Langer B, Langer L.  
*Subepithelial connective tissue graft technique for root coverage.*  
*J Periodontol.* 1985;56(12):715-720.
22. Ishikawa T, Salama M, Funato A, et al.  
*Three-dimensional bone and soft tissue requirements for optimizing esthetic results in compromised cases with multiple implants.*  
*Int J Periodontics Restorative Dent.* 2010;30(5):503-511.
23. Schrottenboer J, Tsao YP, Kinariwala V, Wang HL.  
*Effect of microthreads and platform switching on crestal bone stress levels: A finite element analysis.* *J Periodontol.* 2008;79(11):2166-2172.
24. Yun HJ, Park JC, Yun JH, et al.  
*A short-term clinical study of marginal bone level change around microthreaded and platform-switched implants.* *J Periodontal Implant Sci.* 2011;41(5):211-217.
25. Prasad DK, Shetty M, Bansal N, Hegde C.  
*Crestal bone preservation: A review of different approaches for successful implant therapy.*  
*Indian J Dent Res.* 2011;22(2):317-323.
26. Paolantonio M, Dolci M, Scarano A, et al.  
*Immediate implantation in fresh extraction sockets. A controlled clinical and histological study in man.* *J Periodontol.* 2001;72(11):1560-1571.
27. Rodriguez AM, Orenstein IH, Morris HF, Ochi S.  
*Survival of various implant-supported prosthesis designs following 36 months of clinical function.*  
*Ann Periodontol.* 2000;5(1):101-108.
28. Larjava H. *Oral Wound Healing: Cell Biology and Clinical Management.*  
1st ed. West Sussex, UK. Wiley-Blackwell; 2012: 287.